

Parry-Romberg Syndrome and Temporal Lobe Refractory Epilepsy: Case Report

A Velandia-Martínez, MD¹, MA Ortega-Sanchez, MD¹, SO Martínez-Perez, MD², I Peña, RN¹, O Pradilla, MD³, R Gomez, MD³, A Martínez-Perez, MD^{3,4}

Departments of ¹Neurology, ²Dermatology, ³Neurosurgery, and ⁴Radiology, Carlos Ardila Lulle Medical Center, Santander, Colombia

Case Report

Journal of Epilepsy Research
pISSN 2233-6249 / eISSN 2233-6257

Received January 5, 2018
Revised January 13, 2020
Accepted January 24, 2020

Corresponding author:

A Velandia-Martínez, MD
Department of Neurology, Carlos Ardila Lulle Medical Center, Centro Médico Carlos Ardila Lulle. Torre A - Piso 3 - Módulo 7, Floridablanca, Santander 681004, Colombia
Tel. +57 7 6392626
Fax. +57 7 6392929
E-mail; adrianococo@hotmail.com

The Parry-Romberg syndrome (PRS), also known as hemifacial atrophy, is a rare neurocutaneous disease with the prevalence of 1/700,000 cases. It is more common in women than men, with an early onset of disease usually within the first two decades of life. Even though the etiology of PRS is unknown, it is thought to be a multifactorial disease that involves hereditary, posttraumatic, autoimmune, infectious, and neoplastic factors. There are a variety of systemic manifestations described in PRS including neurological conditions that range from intractable headache to refractory epilepsy. The manifestations must be identified in a timely manner to ensure an early therapeutic intervention, considering that an appropriate approach during the initial phase might halt the disease progression and markedly improve the quality of life in these patients. This article is aimed to describe the case of a 23 years old female with left hemifacial atrophy and dermatologic, dental, and neurologic compromise, associated with refractory temporal lobe epilepsy evidenced in neuroimaging and electrodiagnostic testings. (2019;9:157-160)

Key words: Hemifacial atrophy, Temporal lobe epilepsy, Facial hemiatrophy

Introduction

The syndrome of Parry Romberg, also known as progressive facial hemiatrophy, is a degenerative disorder, which is characterized by affecting the growth and unilateral development of tissues, muscles, cartilage and facial bones.¹⁻³

It is usually accompanied by neurological symptoms such as neuralgia, migraines, and focal seizures, which can be associated with structural brain lesions, as well as ophthalmologic, cardiac, rheumatologic, infectious, endocrine, and maxillofacial abnormalities.⁴ Its etiology is unknown and the syndrome usually arises from childhood. Here, we describe a case of 23-year-old patient with a late diagnosis of Parry-Romberg syndrome (PRS), leading to refractory epilepsy.

Case Report

A 23 years old female patient was consulted to neurology department with left hemifacial atrophy with the involvement of the zygomatic area extending to the left jaw, mouth, and ipsilateral temporo-parietal area (Fig. 1). The patient did not have any other sig-

nificant medical or traumatic history in the past, and there were no history of dental procedures or infections either. The onset of the

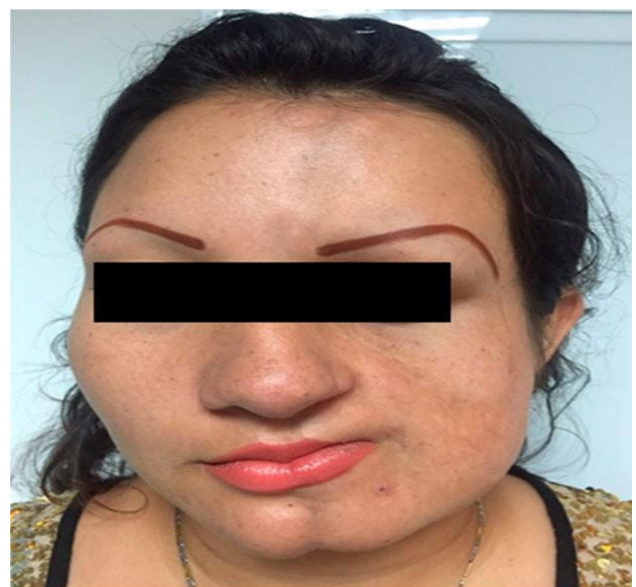

Figure 1. Picture of the patient. Note that the patient has predominant left hemifacial atrophy.

manifestations was at the age of eight with hyperpigmentation in the left zygomatic region and left hemifacial atrophy, and it resulted in severe bone, fat tissue and muscle atrophy of the aforementioned regions after a steady progression during the following 2 years. The disease first developed since the patient was at 8 years old. The diagnosis of PRS was made at the age of 8 by a skin biopsy. Until then, the patient had not received any medications related to this.

In addition to the left hemifacial atrophy, the patient (Figs. 2 and 3) was characterized by atrophy of the ipsilateral upper limb with hypoplasia of the fifth finger of the left hand, left enophthalmos (Fig. 4) as well as eyelid retraction without involvement of the eye movements. Additional cutaneous manifestations included linear scleroderma and bandlike alopecia (Fig. 5). Regarding dental manifestations, the patient presented with radicular resorption of dental organs within the left superior hemiarch without headache or arthralgia. The laboratory tests including complete autoimmune panel showed no abnormal results. Since 2006, the patient was performed seven surgeries for multiple muscle and fat grafting.

The patient was referred to the neuro-epilepsy clinic for her neurological manifestations, which included seizures that initiated at the age of eighteen. It was characterized by a blank stare, supraversion, and tonic posture with extension of the four limbs, followed by tonic tremor and dystonic posture of the hands, sialorrhea, tongue biting,

for about 1-2 minutes, and occasionally postictal confusion. The frequency of seizures was three episodes each month, which did not respond to the first line of anticonvulsants (carbamazepine and valproic acid) for more than 3 months, while adequately controlled by levetiracetam and lacosamide afterwards. The brain magnetic resonance imaging (MRI) revealed focal cortical dysplasia in the left frontal and temporo-polar regions (Fig. 4). The video-electroencephalography (EEG) monitoring for more than 72 hours showed abnormal epileptiform activities in the left fronto-temporo-occipital areas. The cognitive function test was not performed, but the patient reported emotional changes without cognitive dysfunction. The patient eventually diagnosed as major depression.

The patient provided her consent to report this case including all of the images in this article.

Discussion

The PRS was first described by Parry in 1825, and 21 years later, Romberg described the clinical manifestations of the disease more precisely.² It is characterized by the progressive loss of skin, muscle, fat, and occasionally bone on the affected side of the ipsilateral face,⁵ and he also identified systemic manifestations such as joint, neurological, ophthalmological, autoimmune and dental involvements.⁶

The neurological characteristics are the most frequent manifestations of PRS, including cutaneous involvement. Epilepsy is one of the neurological characteristics that can be found in patients with PRS. Commonly, focal seizures with or without impaired consciousness originate in the ipsilateral cerebral cortex of the affected hemiface. A possible hypothesis is that the source of the seizure can be related to the role of chronic encephalopathy, observed in some

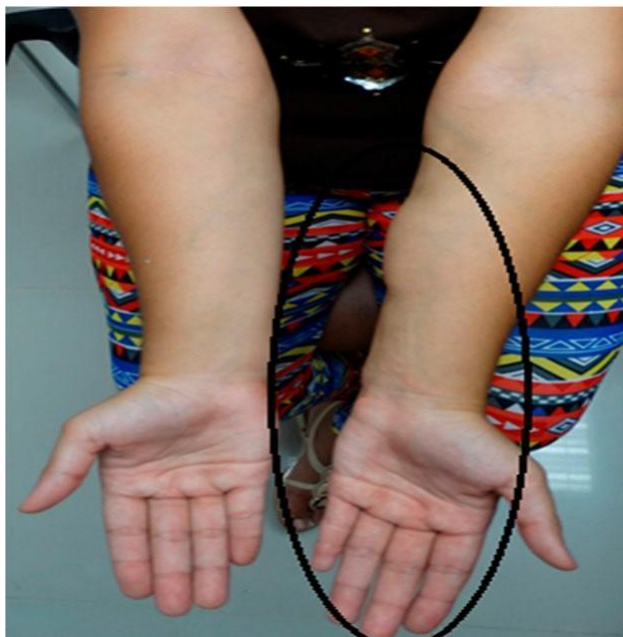

Figure 2. Photo of the patient. Note the abnormality of the left upper limb, especially of the forearm area.




Figure 3. Photo of the patient. Note that the fifth finger of the left hand is hypoplastic.

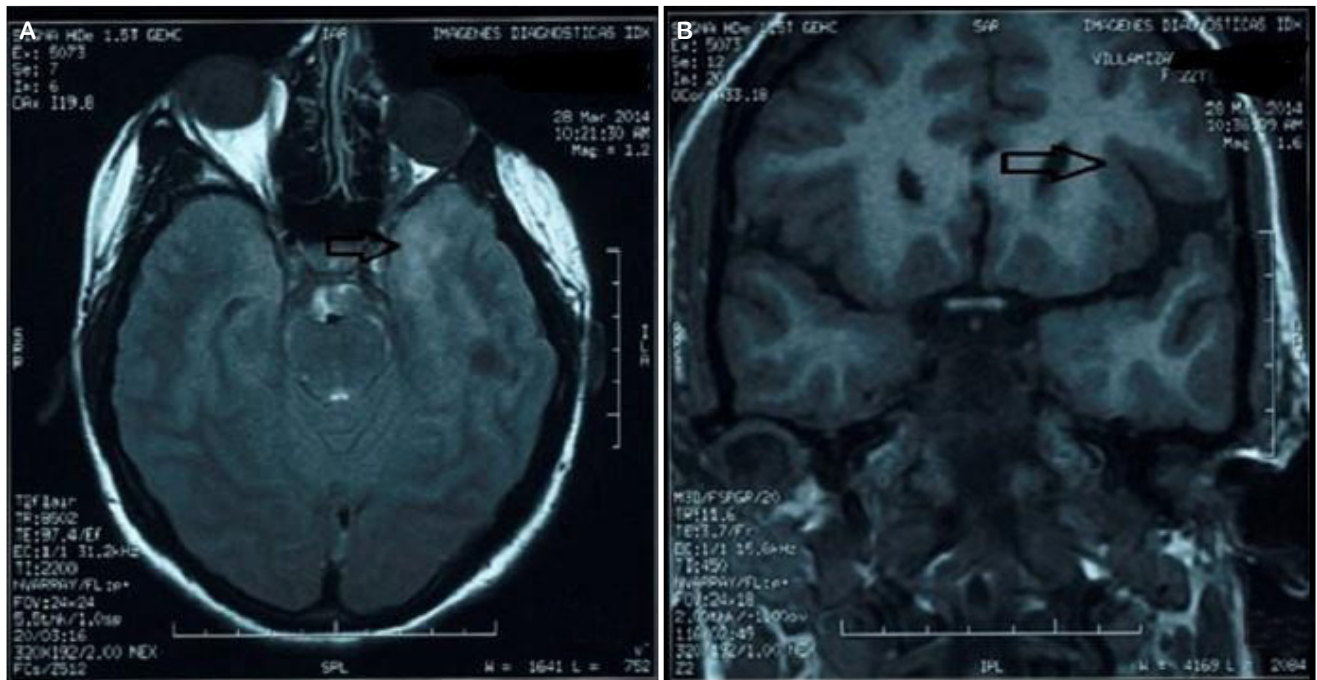


Figure 4. The brain MRI findings. (A) The axial view of the T2 fluid attenuated inversion recovery sequence with the left temporo-polar dysplasia and the ipsilateral enophthalmos, and (B) the coronal view of T1 sequence of the left frontal cortical dysplasia.

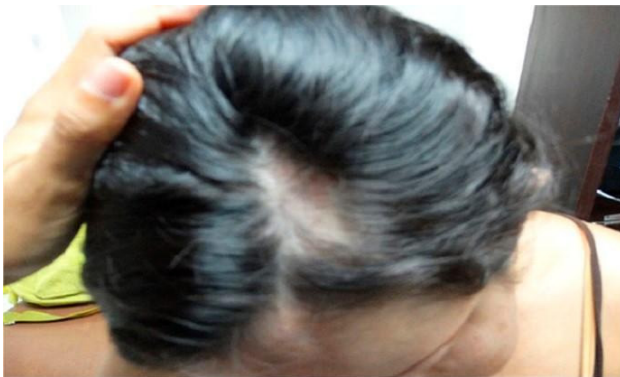

Figure 5. Photo of the patient. Note the partial alopecia in the vertex head region.

patients with epileptiform activities in the ipsilateral cortex of the affected hemiface.⁷ Another neurological manifestation is migraine associated with cranial neuropathies that may be related to cranial nerves III to VII. Due to bone and other anatomical abnormalities, trigeminal neuralgia can be found in association with vascular inflammation with secondary facial pain, which is difficult to be treated pharmacologically.⁸

In the present case, we observed that the patient had symptomatic focal epilepsy, with an abnormal EEG findings with epileptiform ac-

tivities in the left frontotemporo-occipital regions. It was also able to identify the presence of a focal cortical dysplasia in the left frontal region on brain MRI, which develops refractory epilepsy.

The main objective of treatment in the early stages is to stop the active phase of the disease and the standard medication for the active phase is immunosuppressant medications such as methotrexate, mycophenolate, cyclosporine and cyclophosphamide.⁶ Unfortunately, many patients seek medical care after the acute stages of the disease are passed,⁸ where immunosuppressive management cannot prevent progression of the disease. As mentioned previously, they usually end up in refractory epilepsy partly because of this lack of treatment failure in the acute stage.⁷

The PRS is a rare disease with a varied list of systemic complications that include neurological abnormalities, mainly in advanced phases of the disease, which challenges the appropriate control of the manifestations, such as convulsive seizures.

The patient from the presented case above did not have any proper approach during the initial phase with immunosuppressant medication to avoid the progression of the disease, which might be caused by lack of knowledge at the time of the diagnosis; this resulted in difficult-to-treat seizures with first and second line of anti-convulsant medications, leading to refractory epilepsy.

For the presented case, the patient was evaluated by the department of neurology-epileptology at the age of 18, which is 10 years after the disease had developed. In the majority of the patients with PRS, the initial manifestation is idiopathic unilateral facial atrophy and without any exception in every single case, it should be approached by a multidisciplinary team including neurologists, dermatologists, ophthalmologists, plastic surgeons and odontologists especially during the initial phase to avoid future aggravation.

References

1. Stone J. Parry-Romberg syndrome. *Pract Neurol* 2006;6:185-8.
2. DeFelipe J, Segura T, Arellano JJ, et al. Neuropathological findings in a patient with epilepsy and the Parry-Romberg syndrome. *Epilepsia* 2001;42:1198-203.
3. Deshingkar SA, Barpande SR, Bhavthankar JD, Humbe JG. Progressive hemifacial atrophy (Parry-Romberg Syndrome). *Contemp Clin Dent* 2012; 3(Suppl1):S78-81.
4. Lee YJ, Chung KY, Kang HC, Kim HD, Lee JS. Parry-Romberg syndrome with ipsilateral hemipons involvement presenting as monoplegic ataxia. *Korean J Pediatr* 2015;58:354-7.
5. Chokar G, Cerase A, Gough A, et al. A case of Parry-Romberg syndrome and alien hand. *J Neurol Sci* 2014;341:153-7.
6. Lazaridou E, Giannopoulou C, Apalla Z, Fotiadou C, Trigoni A, Ioannides D. Parry-Romberg syndrome. *J Dermatol Case Rep* 2010;4:30-2.
7. Haldar A, Mukherjee A. Parry Romberg's disease with intractable partial epilepsy. *Neurol India* 2007;55:160-2.
8. Tolkachjov SN, Patel NG, Tollefson MM. Progressive hemifacial atrophy: a review. *Orphanet J Rare Dis* 2015;10:39.