

A Severe Dementia Case in End of Life Care with Psychiatric Symptoms Treated by Perampanel

Asaki Kumamoto, MD¹, Yuhei Chiba, MD, PhD¹, Akira Suda, MD, PhD²,
Akitoyo Hishimoto, MD, PhD², Akihiko Kase, MD¹

¹Department of Psychiatry, Sekiaikai Yokohama Maioka Hospital, Yokohama; ²Department of Psychiatry, Yokohama City University Graduate School of Medicine, Yokohama, Japan

Case Report

Journal of Epilepsy Research
pISSN 2233-6249 / eISSN 2233-6257

Epilepsy is known to comorbid with Alzheimer's disease. It can promote cognitive decline, and eventually worsen their prognosis and mortality. It is sometimes difficult to find a suitable drug because of the adverse effects. Perampanel has a unique mechanism of action that antagonizes α -amino-3-hydroxy-5-methyl-4-isoxazolepropionic acid type glutamate receptor. Here, we report a case of severe dementia due to Alzheimer's disease with intractable epilepsy, which perampanel effected for controlling seizures with less adverse effects. The subject is an 89-year-old Japanese woman with severe dementia due to Alzheimer's disease and intractable myoclonic epilepsy. She also had psychiatric symptoms, such as circadian rhythm disorder and irritability. Valproic acid, lacosamide, or carbamazepine were prescribed, but none of them was effective. Shortly after perampanel started, however, myoclonus and these psychiatric symptoms improved. Moreover, it did not cause any obvious adverse effects, which made it possible to continue perampanel until the end of her life. Perampanel may be useful for controlling intractable epilepsy accompanied by Alzheimer's disease. It may also improve psychiatric symptoms with less adverse effect. Accumulation of studies is necessary to evaluate the effectiveness of perampanel on the epilepsy of Alzheimer's disease patients and further understand that mechanism. (2021;11:93-95)

Key words: Perampanel, AMPA receptors, Alzheimer disease, Epilepsy

Received December 7, 2020

Revised January 27, 2021

Accepted February 2, 2021

Corresponding author:

Yuhei Chiba, MD, PhD

Department of Psychiatry, Sekiaikai

Yokohama Maioka Hospital, 3482

Maioka-cho, Totsuka-ku, Yokohama,

Kanagawa 244-0813, Japan

Tel. +81-45-822-2125

Fax. +81-45-823-9757

E-mail: suezan_2000@yahoo.co.jp

Introduction

Alzheimer's disease (AD) is a representative of neurodegenerative diseases, where dementia symptoms gradually worsen over several years and epilepsy is known to comorbid with AD.¹ Epilepsy can promote cognitive decline, and eventually worsens their prognosis and mortality.² Manifestations of complex partial seizures or postictal states, such as inattentiveness, aggression, and delirium, would be difficult to be differentiated with the dementia symptoms.³ It is essential to control seizures in patients with AD. However, finding a suitable anti-epileptic drug for elderly patients is sometimes difficult because of adverse effects such as somnolence, walking disturbance, or dysphagia.

Perampanel is a relatively new anti-epileptic drug and attracts attention in its unique mechanism of action that antagonizes α -amino-3-hydroxy-5-methyl-4-isoxazolepropionic acid (AMPA) type glutamate receptor.^{4,5} Perampanel is reported effective against in-

tractable seizures and useful for sleep disorders associated with epilepsy.^{6,7} Although perampanel can be a new choice for epilepsy with AD, the data does not accumulate enough to consider its effectiveness. We experienced a case of severe dementia due to AD with intractable epilepsy, which perampanel effected for controlling seizures, and further, for improving psychiatric symptom without obvious adverse effects.

Case Report

The subject is an 89-year-old Japanese woman. Cognitive disorder, paranoia, auditory, and visual hallucination gradually appeared when she was in her 70s, and afterwards circadian rhythm sleep disorder and irritability started. She had entered a nursing home 3 years before hospitalization and often shouted or used violence against the caregivers to refuse their care. Furthermore, she was awake nearly all night and kept on calling a staff for several trivi-

al reasons. Although antipsychotic drugs such as risperidone or chlorpromazine started, they were not effective enough and made her drowsy and lost her appetite. Antipsychotic drugs were difficult to continue. She eventually admitted to our psychiatric hospital for inspection and treatment for these symptoms. Her cognitive disorder was so severe that she could not answer any cognitive function test. Her score of Mini-Mental Status Examination was 0 and head computed tomography scan showed diffuse cerebral atrophy, which was especially severe in the hippocampus. She had myoclonus on her left leg, and electroencephalography showed 1.5-7 Hz poly-spikes in the right temporal lobe (Supplementary Fig. 1). Her diagnosis was AD and myoclonic epilepsy. She needed total assistance ever since she had fractured her leg, and the score of Mini Suffering State Examination (MSSE), which evaluates the suffering of end-stage dementia, was 8, meaning the estimated survival rate of less than 20% at 6 months.

Valproic acid, lacosamide, or carbamazepine were prescribed to control seizures and improve psychiatric symptoms. They were used in a sufficient dose and for enough time to determine the effect, but in the result, none of them none was effective. Perampanel 4 mg started as expected in its unique action. Shortly after that, myoclonus and psychiatric symptoms such as shouting and circadian rhythm sleep disorder improved. Moreover, her appetite improved and she began to eat well. There were no abnormal bursts in the electroencephalography performed after perampanel started, which confirmed its effectiveness on epilepsy. Perampanel was reduced to 2

mg, as she got gradually weakened by aging. She could eat without severe swallowing dysfunction until she died of old age about one year after hospitalization.

Discussion

In this case, severe dementia due to AD accompanied myoclonic epilepsy. Valproate, lacosamide, and carbamazepine were not effective against epilepsy. However, perampanel succeeded in controlling seizures (Fig. 1). Psychiatric symptoms, such as shouting and circadian rhythm sleep disorder, definitely worsen the patient's quality of life. It was challenging to determine whether these were psychiatric seizure of epilepsy or behavioral and psychological symptoms of dementia, but anti-epileptic drugs would be useful for these conditions in both cases. However, none of the valproate, lacosamide, and carbamazepine worked, and finally, perampanel improved these symptoms. Glutamate increases in the AD brain, especially severe AD brain, which could induce epileptogenesis. Perampanel antagonizes AMPA type glutamate receptors and might be especially useful for the present case. Moreover, some studies reported that perampanel improves sleep quality,^{7,8} which controls seizures. The present case would suggest that perampanel be very useful in epilepsy of patients with severe dementia due to AD.

A previous study has reported that MSSE is valid for predicting the last 6 months of survival and mortality of end-stage dementia patients,⁹ and the 6-month survival rate of the present case was less than

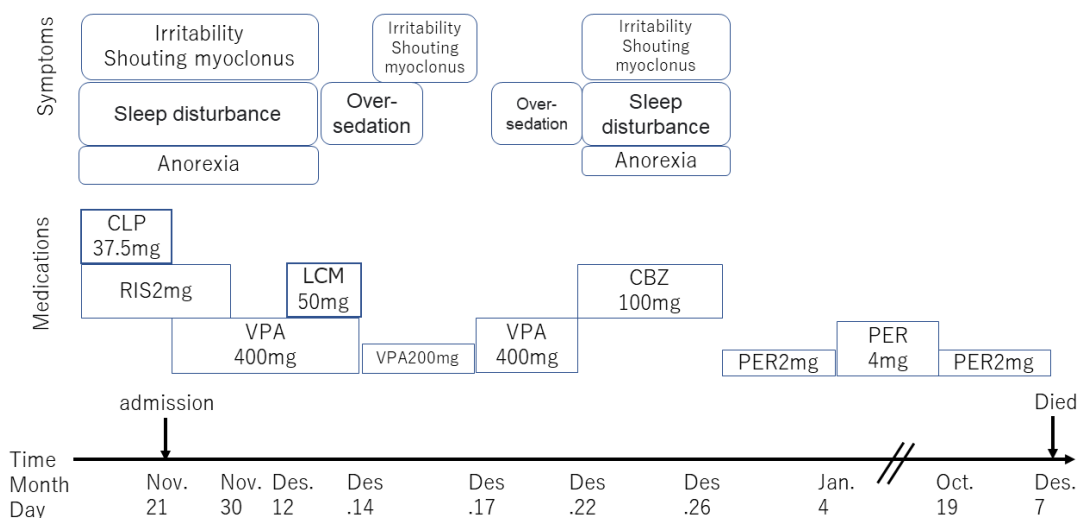


Figure 1. Time course summary of symptoms and treatment of the present case. CLP, chlorpromazine; RIS, risperidone; VPA, valproic acid; LCM, lacosamide; CBZ, carbamazepine; PER, perampanel.

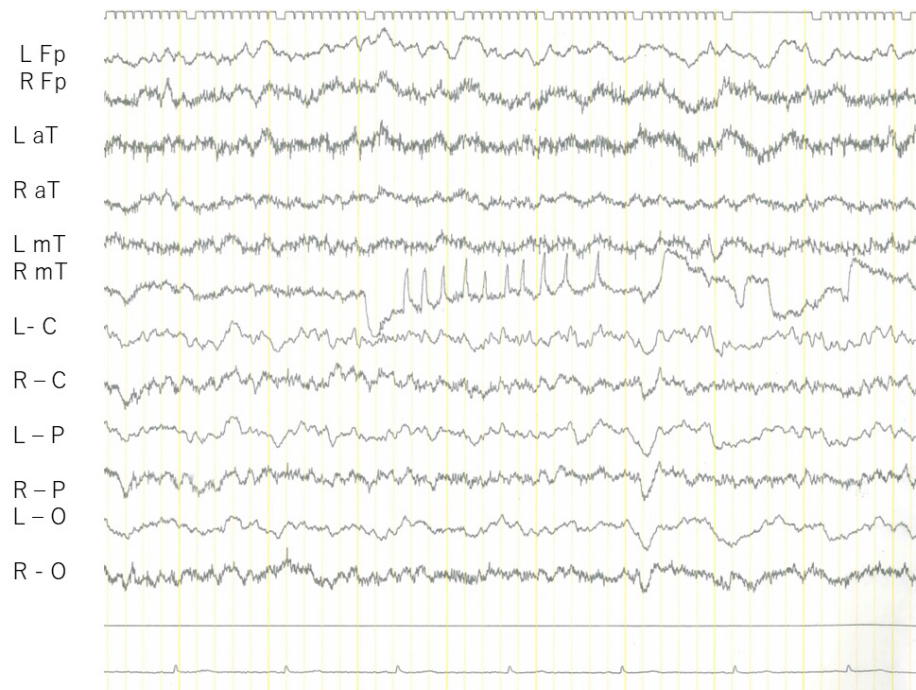
20%. The present case, however, survived at least about a year, though she was with severe dementia needed to be fully supported, and had a high score of MSSE. This fact suggests that perampanel can be used safely in patients in end-stage dementia. In addition, it may also suggest that perampanel may have acted protectively on the brain cells by antagonizing the AMPA receptor as Memantine suppresses the progression of AD by antagonizing the N-methyl-D-aspartate type glutamate receptor.¹⁰ Accumulation of studies is necessary for evaluating the effectiveness of perampanel on the epilepsy of AD patients and further understanding that mechanism.

Conflict of Interest

The authors declare that they have no conflicts of interest.

References

1. Vossel KA, Tartaglia MC, Nygaard HB, Zeman AZ, Miller BL. Epileptic activity in Alzheimer's disease: causes and clinical relevance. *Lancet Neurol* 2017;16:311-22.
2. Lyou HJ, Seo KD, Lee JE, Pak HY, Lee JH. Association of Alzheimer's disease with the risk of developing epilepsy: a 10-year nationwide cohort study. *Dement Neurocogn Disord* 2018;17:156-62.
3. Friedman D, Honig LS, Scarmeas N. Seizures and epilepsy in Alzheimer's disease. *CNS Neurosci Ther* 2012;18:285-94.
4. Rogawski MA, Hanada T. Preclinical pharmacology of perampanel, a selective non-competitive AMPA receptor antagonist. *Acta Neurol Scand Suppl* 2013;(197):19-24.
5. Hanada T, Hashizume Y, Tokuhara N, et al. Perampanel: a novel, orally active, noncompetitive AMPA-receptor antagonist that reduces seizure activity in rodent models of epilepsy. *Epilepsia* 2011;52:1331-40.
6. Huber B, Schmid G. A two-year retrospective evaluation of perampanel in patients with highly drug-resistant epilepsy and cognitive impairment. *Epilepsy Behav* 2017;66:74-9.
7. Toledo M, Gonzalez-Cuevas M, Miró-Lladó J, et al. Sleep quality and daytime sleepiness in patients treated with adjunctive perampanel for focal seizures. *Epilepsy Behav* 2016;63:57-62.
8. Romigi A, Izzi F, Liguori C, et al. Effects of adjunctive perampanel on sleep quality, daytime somnolence and cognition in refractory focal epilepsy: further data. *Epilepsy Behav* 2017;67:137-8.
9. Zvi Aminoff B. Mini-suffering state examination scale: possible key criterion for 6-month survival and mortality of critically ill dementia patients. *Am J Hosp Palliat Care* 2007;24:470-4.
10. Lazzeroni LC, Halbauer JD, Ashford JW, et al. Memantine is associated with longer survival than donepezil in a Veterans Affairs prescription database, 1997 to 2008. *J Alzheimers Dis* 2013;36:791-8.



Supplementary Figure 1. The electroencephalography before perampanel.